



**Chicago
Dermatological
Society**

Monthly Educational Conference

**Program Information
CME Certification
and
Case Presentations**

*Wednesday, April 7, 2021
Online - via Zoom*

Conference Host:



Stroger Hospital of Cook County
Division of Dermatology
Chicago, Illinois

Program

Host: Stroger Hospital of Cook County
Wednesday, April 7, 2021
Online Conference

8:30 a.m.	Sign-in and Member Visitation Time
9:00 a.m.	Welcome & Introduction <i>David Mann, MD - CDS President</i>
9:05 a.m. - 10:00 a.m.	Guest Lecture #1 "Melanocytic Lesions and Uncertainty" <i>Raymond L. Barnhill, MD</i>
10:00 a.m. - 10:35 a.m.	Resident Case Presentations & Discussion <i>Stroger/Cook County Hospital Residents</i>
10:35 a.m. - 11:05 a.m.	Guest Lecture #2 "Angiotropism and Pericytic Mimicry in Melanoma" <i>Raymond L. Barnhill, MD</i>
11:05 a.m.	Closing Remarks <i>David Mann, MD</i>
11:05 a.m. - 12:00 p.m.	Case Discussion <i>Moderated by Joerg Albrecht, MD</i>
12:00 p.m.	Meeting adjourns

Mark the Date!

Next CDS clinical meeting will be on Wednesday, May 5 – Co-hosted by the Rush University.

The next CDS Connections is planned for Tuesday, April 27; 6-8 p.m.

The 2021 President's Meeting is scheduled for Wednesday, June 2. Watch the CDS website for details, coming soon.

Guest Speaker



RAYMOND L. BARNHILL, MD

**Professor, Department of Translational Research,
Institut Curie; Professor, Faculty of Medicine,
University of Paris René Descartes
School of Medicine
Paris, France**

Raymond L. Barnhill, MD, MSc, is Professor of Pathology at the Institut Curie, Department of Translational Research, and he also is a Professor on the Faculty of Medicine, University of Paris René Descartes, in Paris, France. Dr. Barnhill received his medical degree from Duke University and was a postdoctoral fellow and graduate student in the University of Oxford where he earned his MSc degree. He has trained as a dermatologist, anatomic pathologist, and dermatopathologist (University of Miami, 1984; and Yale University, 1985). His academic and research interests largely have been associated with the biology of melanocytic lesions and melanoma, but also all aspects of dermatopathology and more recently ophthalmic pathology. Dr. Barnhill has held major academic leadership appointments including Director of Dermatopathology at Brigham and Women's Hospital and Children's Hospital, Harvard Medical School, and Director of Dermatopathology (tenured professor) at Johns Hopkins University.

Dr. Barnhill has founded both the North American Melanoma Pathology Study Group and, in 2007, the International Melanoma Pathology Study Group, of which he served as President. He has also been an active member of the WHO Melanoma Program and the EORTC Melanoma Group and many other professional societies. In 2011, he received the Founder's Award from the American Society of Dermatopathology. Dr. Barnhill has a distinguished career with numerous leadership positions in dermatology and dermatopathology. He is the author of a substantial number of original articles, chapters and reviews, and the author, co-author, or editor of five books, including three leading textbooks in dermatopathology and the pathology of melanoma.

CME Information

April 7, 2021

Overview

The Chicago Dermatological Society was established in 1901 and has strived to provide meaningful educational opportunities to dermatologists in the Chicago area for more than a century. Guest speakers from across the country share their expertise with CDS members, as well as residents in training medical students doing their dermatology rotation. CDS typically schedules six day-long meetings each year which are "hosted" by one of the dermatology residency programs in the city. Two lectures are given by the guest speaker, and the residents of the host institution present cases which are offered for audience discussion. During the coronavirus pandemic, CDS has continued to organize our regular educational conferences, but in a half-day "virtual" online live setting.

Target Audience

This activity has been designed to meet the educational needs of dermatologists. CDS members, residents in training and medical students engaged in their dermatology rotation are invited to attend.

Learning Objectives

At the conclusion of the April 2021 meeting, the participant should be able to:

1. Discuss the challenges and factors involved in diagnosing melanocytic lesions, and review the incidence of melanoma with respect to these types of lesions.
2. Describe potential difficulties in interpreting the pathological findings of melanocytic lesions.
3. Discuss angiotropism and pericytic mimicry in diagnosing melanoma and how angiotropism can be a prognostic factor in predicting risk for metastasis.

Physician Accreditation Statement

This activity is planned and implemented by Indiana Academy of Ophthalmology (IAO) and the Chicago Dermatological Society. IAO is accredited by the Indiana State Medical Association to provide continuing education for physicians.

Credit Designation for Physicians – IAO designates this live activity for a maximum of 2 *AMA PRA Category 1 Credit(s)*TM. Physicians should claim only the credit commensurate with the extent of their participation in the activity.

Attendees are required to submit an online CME claim form after the completion of the conference. A link to this form along with the online evaluation form will be sent to each conference attendee after the meeting. Thank you for your attention to this important item.

Disclosure of Conflicts of Interest

The IAO and CDS require instructors, planners, managers and other individuals and their spouse/life partner who are in a position to control the content of this activity to disclose any real or apparent conflict of interest they may have as related to the content of this activity. All identified conflicts of interest are thoroughly vetted by IAO and CDS for fair balance, scientific objectivity of studies mentioned in the materials or used as the basis for content, and appropriateness of patient care recommendations. All speakers are asked to follow the "first slide" rule to repeat their conflict of interest disclosures during their talk. The guest speaker, Dr. Raymond Barnhill, disclosed grant support from the Uveal Melanoma (UM) Cure 2020 project under the European Union's Horizon 2020 research and innovation programme (grant agreement No 667787). Period 2015 – 2021; R01CA201376 NIH/NCI 2016-2021. He does not intend to discuss off-label use of commercial products or devices. None of the other participants in this conference have disclosed relevant potential conflicts of interest.

Contact Information

For information about the physician accreditation of this program please contact the CDS administrative office at: 847-680-1666; email: Rich@RichardPaulAssociates.com

Continued next page

Americans with Disabilities Act

In compliance with the Americans with Disabilities Act, we will make every reasonable effort to accommodate your request. For any special requests, contact CDS at: Rich@RichardPaulAssociates.com

Disclaimer

Participants have an implied responsibility to use the newly acquired information to enhance patient outcomes and their own professional development. The information presented in this activity is not meant to serve as a guideline for patient management. Any procedures, medications, or other courses of diagnosis or treatment discussed in this activity should not be used by clinicians without evaluation of patient conditions and possible contraindications or dangers in use, review of any applicable manufacturer's product information, and comparison with recommendations of other authorities.

Disclosure of Unlabeled Use

This educational activity may contain discussion of published and/or investigational uses of agents that are not indicated by the FDA. The planners of this activity do not recommend the use of any agent outside of the labeled indications. The opinions expressed in the educational activity are those of the faculty and do not necessarily represent the views of the planners. Please refer to the official prescribing information for each product for discussion of approved indications, contraindications, and warnings.

Table of Contents

1. Bacillary Angiomatosis.....	1
2. Primary Varicella from Herpes Zoster Exposure.....	5
3. Pseudolymphoma Following Herpes Zoster Infection.....	8
4. Angioinvasive Candida Tropicalis Resulting in Necrotizing Cellulitis.....	11
5. Pembrolizumab Induced Bullous Pemphigoid Reactivation.....	14
6. Atrophic Glossitis Secondary to Iron Deficiency Anemia.....	18
7. Anti-MDA5 Dermatomyositis.....	21
8. Orofacial and Digital Frostbite Due to Inhalant Abuse.....	26

Presented by Tina Hsu MD, Waldemar Niklinski MD, and Joerg Albrecht MD

History of Present Illness

A 71-year-old man presented to clinic with a four-week history of an acute onset papulonodular eruption starting on left knee, then spreading to the extremities and face. Nodules continued to enlarge and increase in number prior to presentation but were not painful or pruritic.

About a year prior to the development of these lesions, the patient was diagnosed with B-cell lymphoma with lymphoplasmacytic differentiation and subsequently treated with rituximab and bortezomib. A few months later, he developed new pancytopenia, and repeat bone marrow biopsy showed hypoplastic marrow without evidence of lymphoma. Patient was started on cyclosporine for aplastic anemia, as well as acyclovir and dapsone for HSV and PCP pneumonia prophylaxis, respectively.

Past Medical History

Lymphoplasmacytic lymphoma
Aplastic anemia

Medications

Cyclosporine 200mg BID
Anti-thymocyte antiglobulin
Acyclovir 400mg BID
Dapsone 100mg QD

Social History

No history of cat exposure, homelessness, pediculosis, or alcoholism

Review of Systems

Positive for chills, loss of appetite, weight loss, headache, fatigue. Negative for fever, arthralgias, pain with urination or defecation, eye pain, blurry vision, abdominal pain, nausea, vomiting, diarrhea, constipation.

Physical Exam

General: A&Ox3, no acute distress
Neck: no lymphadenopathy
Skin: multiple light pink papules and nodules of varying sizes on the upper and lower extremities, multiple dome-shaped red papules and a larger pink nodule on the lateral upper lip

Laboratory Data

The following labs were remarkable/abnormal:

Lab	Value	Normal Range
WBC	1.5 x 10 ³ cells/ μ L	4.4-10.6 x 10 ³ cells/ μ L
Hgb	6.5 g/dl	12.9-16.8 g/dl
Plt	158 x 10 ³ cells/ μ L	161-369 x 10 ³ cells/ μ L
Absolute neutrophil count	275 cells/ μ L	2000-4000 cells/ μ L
CD4	119 cells/mm ³	500-1200 cells/mm ³
SPEP	Monoclonal band seen	None
IFE	IgG kappa	None
Serum K/L ratio	1.78	0.26-1.65

Histopathology

The patient underwent multiple unrevealing punch biopsies. Biopsy of left knee lesion demonstrated fibrous tissue with acute and chronic inflammation, granulation tissue, and focal microabscesses. CMV, HHV-8, and special stains (PAS, Gram, AFB) were negative for microorganisms. Biopsy of two lesions on the right arm demonstrated granulomatous dermatitis, perifollicular fibrosis, and deep fibroblastic proliferation. Biopsy of left forehead lesion showed a pyogenic granuloma.

Excisional biopsy of right arm lesion was suggestive of possible infectious process including bacillary angiomatosis and was sent to the National Institutes of Health for confirmation. The histology demonstrated clusters of vascular proliferation arranged in nodular patterns showing epithelioid endothelia, as well as an inflammatory infiltrate made up of histiocytes and lymphocytes. CD31 and CD34 demonstrated the marked vascular proliferation containing vessels with SMA-positive pericytes. CD3, CD20, CD138, CD1a, CD68, and CD38 highlighted scattered lymphoid cells, plasma cells, and histiocytes with no evidence of lymphoma. CMV, HHV-8, EBER, and special stains (PAS, Gram, AFB) were again negative. Warthin-Starry was performed at NIH and no microorganism was identified. These reactive changes, along with patient's history and labs, were suggestive of bacillary angiomatosis, but needed to be confirmed by further microbiology tests due to the lack of microorganisms found on pathology.

Microbiology

Lab	Value
Blood culture	Negative
AFB culture	Negative
Fungal culture	Negative
Histoplasma antigen	Negative
Quantiferon gold	Indeterminate
Cryptococcal antigen	Negative
HIV	Negative
Bartonella henselae PCR	Negative
Bartonella henselae IgG	Negative
Bartonella quintana PCR	Positive
Bartonella quintana IgG	Negative

Radiology

CT Chest 1/30/2020:

- New ground-glass opacities of the lungs.
- New 1 cm lung nodule in the right lower lobe abutting the diaphragm.
- New small, bilateral pleural effusions.

CT Pelvis 1/30/2020:

- Left buttock abscess measuring 2.8 x 4.1 cm. This is adjacent to the left ischium. No evidence for adjacent osteomyelitis.
- Ill-defined soft tissue density in the right buttock region.
- Two stable subcentimeter liver lesions.
- New small amount of fluid in the cul de sac.

Diagnosis

Bacillary angiomatosis

Treatment and Course

Given the rapid development of new skin lesions, possible hepatic involvement, and significant morbidity associated with untreated bacillary angiomatosis, the patient was treated with intravenous gentamicin 200mg Q48hours for 14 days and oral doxycycline 100mg BID for four months. Following the four-month course of doxycycline, the patient did not have significant improvement in his skin lesions, and doxycycline 100mg BID was continued. The patient is currently being worked up for his aplastic anemia, the differential for which includes secondary hypoplastic myelodysplastic syndrome. Given that the patient does not have bacillary angiomatosis secondary to HIV or another readily treatable cause of immunosuppression, it is not unexpected that these lesions have persisted despite treatment and may require surgical excision in the future.

Discussion

Bartonella is a genus of Gram-negative bacteria, and *Bartonella* subspecies can cause a wide range of diseases, including bartonellosis, bacillary angiomatosis, cat scratch disease, trench fever, and endocarditis. Bacillary angiomatosis, a rare condition most commonly seen in patients with HIV or advanced immunosuppression, classically presents as a pink papule on the upper extremities that develops into a violaceous nodule that ranges from a few millimeters to a few centimeters in diameter. The lesion may ulcerate or bleed as it enlarges. Additional papules and nodules may develop on cutaneous and mucosal surfaces.

Patients with bacillary angiomatosis can have fever, chills, anorexia with or without weight loss. In addition, they may have gastrointestinal bleeding secondary to lesions in the gastrointestinal tract or neuropsychiatric complaints secondary to intracerebral lesions. It is notable that our patient had no systemic symptoms, which is unusual in HIV patients, but has been described. Although infection with either *B. henselae* or *B. quintana* can result in bacillary angiomatosis, subcutaneous and osseous lesions are more commonly seen with *B. quintana*, while hepatosplenic lesions are more frequently associated with *B. henselae*.

The diagnosis of bacillary angiomatosis is usually made based on a combination of clinical manifestations, histopathology, and serologic studies. Isolation of the organism is extremely difficult, and therefore culture is not recommended. Histology appearance on low power is one of pyogenic granuloma or granulation tissue. Diagnosis of bacillary angiomatosis is then made based on a combination of dermal or subcutaneous diffuse infiltrates of neutrophils and pale, smudgy amphophilic areas that contain the organisms (sometimes visible with H&E). Microorganisms can be seen on Warthin-Starry stain. In our patient no organisms could be seen.

Serologic studies that support a diagnosis of *Bartonella* infection include an IgM titer of 1:16 or greater, which is suggestive of an early recent infection, as well as an IgG titer of 1:256 or greater, which is suggestive of a current or past *Bartonella* infection. PCR-based detection of *Bartonella* target genes in tissue specimens is generally sensitive in diagnosing bacillary angiomatosis, but results may depend on the quality of the laboratory performing the study.

Bacillary angiomatosis is effectively treated with antibiotics, most frequently oral doxycycline or erythromycin. In patients with hepatic or osseous involvement, intravenous therapy is preferred, and in patients with central nervous system involvement, a combination regimen of doxycycline and rifampin has been recommended. Improvement of the immune response, such as antiretroviral therapy in a patient with HIV/AIDS, is essential to prevent relapses after cessation of therapy. Adjunctive procedures, such as cryotherapy, electrodesiccation with curettage, and surgical excision of solitary cutaneous lesions, may be performed. Current recommendations

state that a baseline *Bartonella* IgG should be checked prior to starting antimicrobial therapy and every six to eight weeks thereafter, with the goal of achieving at least a four-fold decline in *Bartonella* IgG titer.

References

1. Claasens S, Schwartz IS, Jordaan HF, Schneider JW. Bacillary angiomatosis presenting with polymorphic skin lesions. *IDCases*. 2016;6:77-78.
2. Diaz MH, Bai Y, Malania L, et al. Development of a novel genus-specific real-time PCR assay for detection and differentiation of *Bartonella* species and genotypes. *J Clin Microbiol* 2012; 50:1645.
3. Diddi K, Chaudhry R, Sharma N, Dhawan B. Strategy for identification & characterization of *Bartonella henselae* with conventional & molecular methods. *Indian J Med Res*. 2013 Feb;137(2):380-7.
4. Diniz LM, Medeiros KB, Landeiro LG, Lucas EA. Bacillary angiomatosis with bone invasion. *An Bras Dermatol*. 2016 Nov-Dec;91(6):811-814.
5. Foucault C, Brouqui P, Raoult D. *Bartonella quintana* characteristics and clinical management. *Emerg Infect Dis*. 2006 Feb;12(2):217-23.
6. Koehler JE, Quinn FD, Berger TG, et al. Isolation of *Rochalimaea* species from cutaneous and osseous lesions of bacillary angiomatosis. *N Engl J Med* 1992; 327:1625.
7. Koehler JE, Tappero JW. Bacillary angiomatosis and bacillary peliosis in patients infected with human immunodeficiency virus. *Clin Infect Dis*. 1993 Oct;17(4):612-24.
8. LeBoit PE, Berger TG, Egbert BM, et al. Epithelioid haemangioma-like vascular proliferation in AIDS: manifestation of cat scratch disease bacillus infection? *Lancet* 1988; 1:960.
9. Rodriguez O, Campbell LR, Bacha JM, Kovarik CL. Successful treatment of bacillary angiomatosis with oral doxycycline in an HIV-infected child with skin lesions mimicking Kaposi sarcoma. *JAAD Case Rep*. 2016 Jan;2(1):77-9.
10. Rolain JM, Brouqui P, Koehler JE, et al. Recommendations for treatment of human infections caused by *Bartonella* species. *Antimicrob Agents Chemother* 2004; 48:1921.
11. Spach DH, Panther LA, Thorning DR, Dunn JE, Plorde JJ, Miller RA. Intracerebral bacillary angiomatosis in a patient infected with human immunodeficiency virus. *Ann Intern Med*. 1992 May 01;116(9):740-2.

Presented by Camila Antia MD and Jerry Feldman MD

History of Present Illness

A 45-year-old male presented to the emergency department with a 2 day history of a pruritic rash to the scalp, face, upper trunk, arms, thighs, and groin. He endorsed a subjective fever, sore throat, eye discomfort, polyuria, and polydipsia. He denied any medication use, new products, or interference with sleep. Of note, no other household members complained of similar symptoms other than his mother, who recently had a painful vesicular dermatomal rash, which was diagnosed and treated as herpes zoster by her primary care provider.

Past Medical History

None

Medications

None

Social History

Occupation: Works in factory
Living situation: Mother, sister, and nephew
Sexual history: Sexually active with women
Recreational drug use: Denied

Review of Systems

Positives per HPI; Denied chills, cough, loss of taste, loss of smell, arthralgias, abdominal pain, diarrhea, or constipation.

Physical Exam

Non-Skin:	General: No acute distress, alert and oriented x 3, well-appearing, pleasant
Skin:	Fitzpatrick skin phototype: IV
Bilateral eyes:	Conjunctival injection
Scalp:	Multiple papules and punched out erosions
Hard palate:	Round, erythematous macules with a white center
Face, upper chest, forearms, upper/inner thighs, scrotum and groin:	4-6 mm papules and papulovesicles. Lesions are in different stages with some intact and some with overlying serum crust. Few punched out erosions
Interdigital spaces:	Few erythematous papules
Palms:	Clear

Laboratory Data

The following labs were remarkable/abnormal:

HSV 1 DNA	Negative
HSV 2 DNA	Negative

VZV DNA
COVID 19

Positive
Negative

Histopathology

Tzanck smear was suggestive of multinucleated giant cells and nuclear molding

Diagnosis

Primary Varicella

Treatment and Course

The patient was treated with valacyclovir 1g three times a day for 10 days . He returned to clinic 2 weeks later with a few crusted papules and almost complete resolution.

Discussion

Primary varicella is caused by the varicella zoster virus (VZV), a highly contagious virus. Since the advent of vaccination against VZV in 1995, the cases of primary varicella have continually declined. In the United States, varicella vaccine coverage is high and circulating wild type VZV is low.

Herpes zoster (HZ) occurs secondary to reactivation of VZV presenting as a localized, dermatomal, painful cutaneous eruption. HZ is thought to be less contagious than varicella as the primary route of infection is direct contact with the vesicle fluid. However, a recent case report described an outbreak in a long-term facility where an elderly patient with HZ was linked to 3 VZV infections (2 other residents and 1 employee) despite lack of direct contact. Another study demonstrated that covering lesions strictly with clothing or gauze resulted in environmental contamination with VZV DNA; however, lesions covered with an occlusive hydrocolloid dressing completely eliminated shedding into the environment. This raises the question of whether VZV is disseminated via droplet or airborne transmission. Given the lack of contact, there is a distinct possibility of aerosolized virus from the skin or respiratory tract as the culprit in these cases.

Current infection control guidelines recommend individuals with HZ to keep lesions covered, but do not recommend isolation or respiratory droplet precaution for those in direct contact. Recent findings of VZV DNA from the throat of patients with HZ suggest that this may be inadequate to prevent all VZV transmission from individuals with HZ. Although not fully understood, viral DNA in the saliva and blood of patients with HZ is well recognized and the spread to the surrounding environment is of concern. Our patient adamantly denied any direct contact with his mother's HZ lesions as they were covered. However, he did change her bedding which may have been a source for his infection through aerosolized particles in the environment.

The decision to initiate antiviral therapy depends upon the patient's age, the presence or absence of comorbid conditions, and the overall clinical presentation. Although varicella is usually a self-limited disease, complications can be can be life-threatening. Pneumonia is the most serious complication and leading cause of death in adults with primary varicella, regardless of their immune status. In one study, the mortality rate for patients with advanced immunosuppression who developed pneumonia was found to be 43%. Other complications to be aware of include hepatitis, pancreatitis and encephalitis

In summary, current guideline for immunocompetent patients with dermatomal HZ only require standard contact precautions, without any mention of airborne or contact isolation precautions. However, HZ may be infectious even when lesions are covered. Aerosolised virus from skin, and possibly from the respiratory tract, may cause infections in patients who are not in direct contact with the index case patient. Given the concern for droplet or airborne transmission, the current guidelines come into question. Covering HZ lesions with gauze may be inadequate and we should recommend hydrocolloid dressings and advise airborne protection for our patients who are more vulnerable.

References

1. J Breuer J. Herpes zoster: New insights provide an important wake-up call for management of nosocomial transmission. *J Infect Dis* **2008**; 197(5):635–637
2. Johnson JA, Bloch KC, Dang BN. Varicella reinfection in a seropositive physician following occupational exposure to localized zoster. *Clin Infect Dis* 2011; 52:907.
3. Leung J, Harpaz R, Baughman AL, et al. Evaluation of laboratory methods for diagnosis of varicella. *Clin Infect Dis* 2010; 51:23–32.
4. Lopez AS, Burnett-Hartman A, Nambiar R, et al. Transmission of a newly characterized strain of varicella-zoster virus from a patient with herpes zoster in a long-term-care facility, West Virginia, 2004. *J Infect Dis* 2008; 197:646–53
5. United States Centers for Disease Control and Prevention. Infection Control in Healthcare Personnel: Infrastructure and Routine Practices for Occupational Infection Prevention and Control Services
6. <https://www.cdc.gov/infectioncontrol/guidelines/healthcare-personnel/index.html>
7. Suzuki K, Yoshikawa T, Tomitaka A, Matsunaga K, Asano Y. Detection of aerosolized varicella-zoster virus DNA in patients with localized herpes zoster. *J Infect Dis* 2004; 189:1009–12
8. Suzuki K, Yoshikawa T, Tomitaka A, Suzuki K, Matsunaga K, Asano Y. Detection of varicella-zoster virus DNA in throat swabs of patients with herpes zoster and on air purifier filters. *J Med Virol* 2002; 66: 567–70.

Presented by Joanna Jaros, MD, Marylee Braniecki, MD and Shilpa Mehta, MD

History of Present Illness

A 46-year-old woman with a past medical history of hypertension and hepatic steatosis presented to dermatology clinic with scars after herpes zoster infection and a new raised lesion on the nose. Two months prior, the patient reported clear, fluid-filled blisters in a dermatomal distribution on the right forehead and nose. She was treated with cephalexin for seven days by her primary care physician for a presumed superinfection. The blisters resolved with scars. Her only other medication was chlorthalidone.

Past Medical History

PMH: Hypertension, hepatic steatosis

FH: Negative for any skin conditions

Medications

Chlorthalidone 25mg daily (>1 year)

Social History

Negative for ETOH/tobacco/illicit drugs

Works in air filter production factory

No recent travel

Review of Systems

Negative for fevers/chills, weight changes, night sweats, arthralgias, bruising, facial sensory or motor disturbance, visual or hearing changes.

Physical Exam

Non-Skin: Alert and oriented, pleasant, in no acute distress

Skin:

Right forehead: multiple, coalescing hyperpigmented macules with three atrophic light brown plaques with sharp borders

Right medial eyebrow: light brown plaque with sharp borders

Dorsal nose: New 1x1.2 cm oval erythematous plaque with minimal scale.

Right nasal ala: light brown macules and light brown atrophic plaques.

Right cheek near nasolabial fold: light brown atrophic plaque.

Oral mucosa: clear

Nails: clear

Laboratory Data

The following labs were remarkable: N/A

Histopathology

1. 10/2020 Left nasal bridge shave biopsy showed mild epidermal spongiosis and epidermal exocytosis and a dense infiltrate of B and T lymphocytes and plasma cells extending into the reticular dermis. The ratio of B to T lymphocytes is

- approximately 1:1. Immunostaining for CD3, 4, 7, 8, and 20 showed positive uptake.
- 12/2020 Left nasal bridge repeat shave biopsy showed an unremarkable epidermis and dense infiltrate of B and T lymphocytes and plasma cells extending to the reticular dermis (base of specimen). The ratio of B to T lymphocytes is approximately 1:1. Immunostaining for CD3, 4, 7, 8, and 20 showed positive uptake. CD 138 stain for plasma cells showed positive uptake. Kappa and lambda staining revealed polyclonality. Stains for HSV-II and EBV were negative.

Microbiology

N/A

Radiology

N/A

Diagnosis

Pseudolymphoma following herpes zoster infection

Treatment and Course

The patient was treated with tacrolimus 0.1% topical ointment twice daily for two months with resolution of the nasal lesion. However, the lesion recurred two weeks following cessation of treatment. At the follow up, a decision was made to re-biopsy to exclude a lymphoma. The second biopsy was consistent with pseudolymphoma, and additional kappa and lambda staining revealed polyclonality. Stains for HSV-II and EBV were negative. The patient was restarted on tacrolimus 0.1% ointment twice daily for two months with full resolution of the lesion. No further recurrence was noted.

Discussion

Pseudolymphomas (PSL) are benign skin disorders mimicking B or T cell cutaneous lymphomas. Common causes of pseudolymphomas include viral infections (Borrelia, VZV, HSV, HIV), drug reactions, arthropod bites, tattoos, injected substances, and foreign body reactions.^{1,2} The development of pseudolymphoma at a site of prior zoster infection is rare, and approximately 10 case reports of pseudolymphomas arising at sites of active or resolved VZV or HSV infections exist in the literature.³⁻⁷ The time interval between infection and the development of pseudolymphoma is highly variable in the literature, ranging from a few days to years.^{3-5,7,8}

Pseudolymphomas commonly present as erythematous, pink to violaceous dermal plaques, papules, and nodules with no epidermal change. Multiple nodules or plaques and lymphadenopathy raise suspicion for lymphoma, and a biopsy is indicated to exclude malignancy and other granulomatous or infectious etiologies.⁸ On histology, pseudolymphomas demonstrate a mixed B and T cell infiltrate – as seen in our patient. Lymphocytes are moderate to large in size and admixed with dendritic cells, B cells, and macrophages. On immunohistochemistry, T cell markers (CD3, CD4, CD5, CD7, CD8) are usually preserved, and T-cell rearrangement is negative.⁸ Presence of a deep infiltrating bottom-heavy, monomorphic infiltrate, high-grade atypical lymphocytes, and loss of T cell markers are suggestive of a lymphoma.

Although the reason for development of a pseudolymphoma following VZV infection remains unclear, a proposed mechanism is Wolf's isotopic response. This phenomenon describes the development of a new, unrelated disease at the site of a previously resolved condition. The proposed mechanism is an atypical, delayed-type

hypersensitivity reaction in response to a virus or an altered host tissue antigen³. Ruocco *et al* documented a collection of 176 cases of a delayed cutaneous reaction following VZV infection, and eight of these cases presented with pseudolymphoma. The most common response was a granulomatous infiltrate (64 cases). The authors postulated that VZV and HSV damage cutaneous nerve endings and alter host immune responses for months after visible lesions have healed.⁵

Pseudolymphoma has good prognosis and management depends on the underlying disease process. If the etiology is related to an antigenic stimulus, the stimulus must be removed. Treatment of a post-infectious pseudolymphoma includes topical corticosteroids (TCS) and calcineurin inhibitors in addition to the appropriate treatment of the underlying infection. In patients with tattoo-related pseudolymphoma, surgery and laser therapy may be considered in addition to TCS.⁸ Drug-associated pseudolymphoma has been reported following anti-epileptics, antihistamines, and certain antibiotics and is treated via drug discontinuation.⁸ Our patient was on chlorthalidone, which has not been associated with development of pseudolymphoma. Patients should be counseled to expect possible macular post-inflammatory hyperpigmentation upon lesion resolution.

We present this case to highlight the diagnostic and management challenges of cutaneous pseudolymphomas. Given that histopathology is often inconclusive, close monitoring is needed to exclude a true lymphoma. Monoclonality and loss of T cell markers can signal a lymphoma. We highlight that pseudolymphomas tend to respond to treatment and may even spontaneously resolve, whereas lymphomas are treatment-resistant. Finally, unresolved antigenic stimulation of a pseudolymphoma can lead to the development of a lymphoma over time.

References

1. Bologna JL, Schafferm JV, Cerroni L. *Dermatology*. Vol 4e: Elsevier-Health Sciences Division; 2017.
2. Albrecht J, Fine LA, Piette W. Drug-associated lymphoma and pseudolymphoma: recognition and management. *Dermatol Clin*. 2007;25(2):233-244, vii.
3. Kwon CW, Stephens DM, Gilmore ES, Tausk FA, Scott GA. Cutaneous Pseudolymphoma Arising as Wolf's Post-Herpetic Isotopic Response. *JAMA dermatology*. 2017;153(11):1198-1200.
4. Moreira E, Lisboa C, Azevedo F, Principe F, Lima M. Postzoster cutaneous pseudolymphoma in a patient with B-cell chronic lymphocytic leukaemia. *J Eur Acad Dermatol Venereol*. 2007;21(8):1112-1114.
5. Ruocco V, Ruocco E, Brunetti G, Russo T, Gambardella A, Wolf R. Wolf's post-herpetic isotopic response: Infections, tumors, and immune disorders arising on the site of healed herpetic infection. *Clin Dermatol*. 2014;32(5):561-568.
6. Wolff HH, Wendt V, Winzer M. Cutaneous pseudolymphoma at the site of prior herpes zoster eruption. *Arch Dermatol Res*. 1987;279 Suppl:S52-54.
7. Sanchez JL, Mendez JA, Palacio R. Cutaneous pseudolymphoma at the site of resolving herpes zoster. *Arch Dermatol*. 1981;117(6):377.
8. Miguel D, Peckruhn M, Elsner P. Treatment of Cutaneous Pseudolymphoma: A Systematic Review. *Acta Derm Venereol*. 2018;98(3):310-317.

Key location(s): Left Leg

CASE 4

Presented by Jeena Sandhu MD, Solomiya Grushchak MD, Jesse Jiang, MD, and Joerg Albrecht MD, PhD

History of Present Illness

A 67-year-old male with a history of chronic lymphocytic leukemia (CLL) in remission and newly diagnosed B-cell lymphoma status post one cycle of R-CHOP presented with left lower extremity pain, redness, and blistering. Seven days prior to presentation, the patient was admitted to the intensive care unit for neutropenic fever and sepsis secondary to pneumonia. He was started on broad spectrum antimicrobials, which included vancomycin, meropenem, and fluconazole before being switched to voriconazole for increasing concern of fungemia.

Past Medical History

CLL
B-cell lymphoma
Chronic hepatitis B

Medications

Vancomycin
Meropenem
Voriconazole
Acyclovir
Pantoprazole
Tenofovir

Social History

Tobacco use: 1-2 cigarettes per day for 50 years
Alcohol use: None
Drug use: None

Review of Systems

Negative except for LLE pain

Physical Exam

General: Alert and oriented. No acute distress.

Skin:

Left lower extremity: Indurated and edematous plaques with overlying tense bullae and dry hemorrhagic crust.
Erythema and induration extended to the knee posteriorly.
No signs of petechiae, purpura, or crepitus.
2+ pitting edema of the dorsal foot to the knee.

Laboratory Data

The following labs were remarkable/abnormal:

WBC	3.2	[4.4 - 10.6 k/uL]
Neutrophils	63.0	[45.3-74.5 %]
HGB	7.1	[12.9 -16.8 g/dL]
HCT	20.1	[38.1 – 49.0 %]
PLT	18	[161- 369 k/uL]

Histopathology

Left lower extremity near edge of hemorrhagic bullae, punch biopsy x 2 for H&E and cultures:

H&E: Skin with epidermal necrosis, superficial ulcer, prominent acute and chronic inflammation extending to subcutaneous tissue, abscess formation and thrombosis

PAS and GMS: Numerous angio-invasive fungal elements containing large septate hyphae and budding yeasts.

Gram stain and AFB stain: Negative

Microbiology

Bacterial Culture of Left Leg: No growth

Fungal Culture of Left Leg: 4+ *Candida tropicalis*

Radiology

CT Scan of Left Lower Extremity:

Skin thickening with diffuse infiltration of the subcutaneous fat with haziness and fascial thickening. The constellation of findings can be seen in the setting of cellulitis and/or edema. No evident soft tissue gas, loculated or rim-enhancing fluid collection, or osteomyelitis of the left lower extremity.

Diagnosis

Angio-Invasive *Candida tropicalis* resulting in Necrotizing Cellulitis

Treatment and Course

Punch biopsy revealed pleomorphic fungal elements within the vessels, prompting a switch from voriconazole to amphotericin B due to concern for mucormycosis. Three days later, fungal culture of grew 4+ *Candida tropicalis*. In the interim, the lesions continued to progress prompting LLE debridement by surgery. Source control remained poor and an above the knee amputation was performed. Eventually, the patient was started on caspofungin after his hemodynamic and mental status continued to decline. CT abdomen showed a splenic infarct, pleural effusions, small volume ascites, psoas hematoma, and lymphoma involvement. The patient was intubated and put on intravenous pressor support. After a palliative care meeting with the family, the patient was made DNR/DNI, placed on comfort care, and passed away several days later.

Discussion

Patients with neutropenia and hematologic malignancies are at a higher risk for developing opportunistic mycotic infections. Many species of *Candida* are opportunistic pathogens and can present with a wide range of cutaneous findings, including necrotic papulonodules, plaques, and hemorrhagic bullae. Of these species, *Candida tropicalis* is becoming a more recognized pathogen as the causative agent of fungemia in patients with hematologic malignancies, particularly leukemia.

In cases with cutaneous manifestations, skin biopsy, fungal culture, and PCR can aid in the diagnosis. Skin biopsies can guide management, however histopathologic findings can be difficult to interpret due to false negative GMS stains or tissue distortion resulting in false septae. Thus, precise speciation can only be achieved with a fungal culture or PCR. On average, it takes 1-3 days to obtain a fungal culture for *Candida* spp, 3-4 days for *Aspergillus*, and 1-2 days for *Mucor*. Hence, this makes empiric treatment critical in the management of patients with high suspicion for opportunistic fungal infections when fungal PCR is unavailable.

When an unknown systemic fungal infection is suspected, broad spectrum treatment with amphotericin B is recommended. Amphotericin b and posaconazole cover all of the major opportunistic pathogens, including *Candida*, *Mucor*, *Aspergillus*, *Cryptococcus*, *Fusarium*, and *Talaromyces marneffeii*. In recent literature, voriconazole has greater efficacy for treatment of invasive *Aspergillus*, *Fusarium*, and *Candida* infections, but does not cover for *Mucormycetes*. Caspofungin is more specific to treatment of *Candida* and *Aspergillus* and is recommend in cases of non-neutropenic candidemia. Lastly, in cases of *Candida tropicalis*, it is important to note that management can be complicated by increasing multi-drug resistance.

References

1. Ben-Ami R. "Treatment of Invasive Candidiasis: A Narrative Review". *Journal of Fungi (Basel)*. 2018;4(3):97. doi:10.3390/jof4030097
2. Berger AP, Ford BA, Brown-Joel Z, Shields BE, et al. "Angioinvasive fungal infections impacting the skin: Diagnosis, management, and complications." *Journal of the American Academy of Dermatology*. 2019;80(4):883-898. doi: 10.1016/j.jaad.2018.04.058.
3. Elewski BE, Hughey LC, Hunt KM, and Hay RJ. "Fungal diseases." In: Bologna J, eds. *Dermatology*. 4th ed. Elsevier, 2017; 1357-1362.
4. Krishnan N, Patel B, Palfrey W, Isache C. "Rapidly progressive necrotizing cellulitis secondary to *Candida tropicalis* infection in an immunocompromised host." *IDCases*. 2020;19:e00691. doi: 10.1016/j.idcr.2019.e00691
5. Pedraz J, Delgado-Jiménez Y, Pérez-Gala S, Nam-Cha S, et al. "Cutaneous expression of systemic candidiasis." *Clinical and Experimental Dermatology*. 2009; 34: 106-110. <https://doi.org/10.1111/j.1365-2230.2007.02524.x>
6. Shields BE, Rosenbach M, Brown-Joel Z, Berger A, et al. "Angioinvasive Fungal Infections Impacting the Skin: Background, Epidemiology, and Clinical Presentation (Part 1)." *Journal of the American Academy of Dermatology*. 2019; 80(4):869-880. doi:10.1016/j.jaad.2018.04.059

Presented by Solomiya Grushchak MD and Joerg Albrecht MD

History of Present Illness

A 67-year-old male with a significant past medical history of bullous pemphigoid in remission following two rituximab 1000mg infusions presented with generalized pruritus and a blistering skin rash on the face, trunk, extremities, and gingiva. Twelve weeks prior, the patient was diagnosed with metastatic non-small cell lung adenocarcinoma and was started on pembrolizumab. He received 4 infusions at 3-week intervals prior to developing this rash.

Past Medical History

Normocytic anemia
Metastatic non-small cell lung adenocarcinoma
Bullous pemphigoid

Medications

None

Social History

Tobacco (2 packs/day)

Review of Systems

Negative for fever, shortness of breath, dysphagia, odynophagia, oral or genital lesions
Positive for chills and fatigue

Physical Exam

Face, trunk, and extremities: Numerous scattered vesicles and bullae on an erythematous base, many with crusted erosions

Oral mucosa:

Prominent gingivitis of the gums

Lymph nodes: 3.5 x 2.5cm non-tender right supraclavicular mass

Laboratory Data

The following labs were remarkable/abnormal:

Eosinophils 4.3 k/uL [Normal <0.4 k/uL]

BP180 antibody

160 U/mL

[Normal ≤ 14 U/mL]

Histopathology

Left forearm, punch biopsy:

Subepidermal blister formation with spongiosis, mild hyperkeratosis with superficial dermal perivascular lymphocytic infiltrate with scattered neutrophils and eosinophils.

Left forearm, DIF punch biopsy:

Linear deposition of IgG and C3 along the basement membrane.

Imaging

PET-CT:

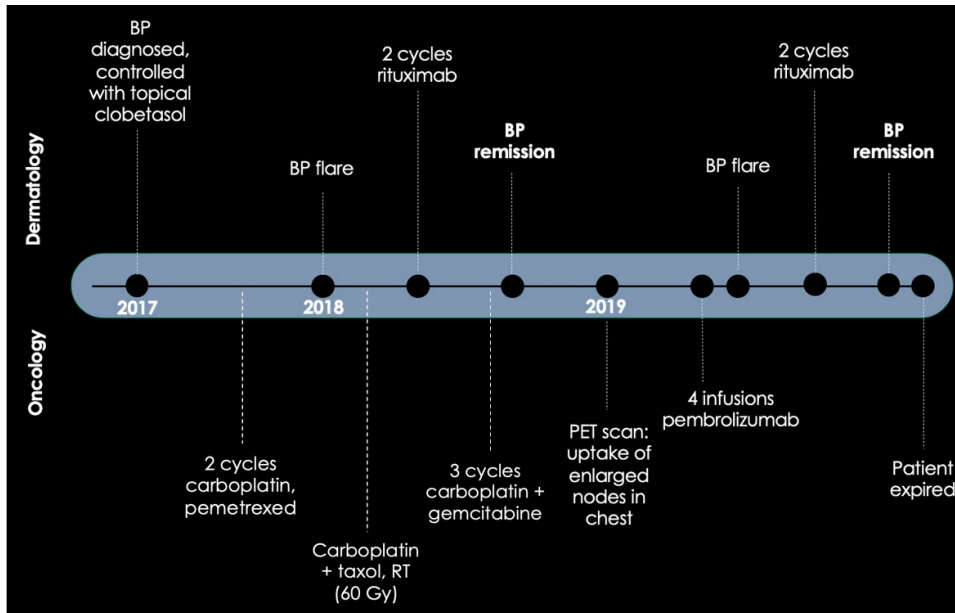
Several enlarged, hypermetabolic lymph nodes in the right supraclavicular and subcarinal region.

Diagnosis

Pembrolizumab induced bullous pemphigoid reactivation

Treatment and Course

Pembrolizumab was held as the patient began treatment for his bullous pemphigoid (BP) with topical steroids, oral prednisone 60mg daily, and dapsone 100mg daily. His skin disease minimally improved with involvement of half his body surface area. His course was complicated by methicillin-sensitive *Staphylococcus aureus* (MSSA) bacteremia and discitis requiring long-term intravenous antibiotics. After a consensus with his oncology team, rituximab was re-administered given his previous response and all other oral medications were discontinued after a slow taper. At a 2-month follow-up visit, his skin disease had significantly improved with only several small areas of pruritus and erythema. A second cycle of rituximab was administered 6 months after the initial infusion. While the patient's BP resolved entirely, his lung adenocarcinoma continued to progress and he unfortunately expired from complications of lung cancer.



Discussion

Bullous Pemphigoid (BP) is an acquired, chronic, autoimmune blistering disease due to IgG autoantibodies to BP180 and BP230. New onset BP with PD-1 or PD ligand-1 (PD-L1) inhibitor use is well known; however, few cases highlight reactivation of immunobullous disease previously in clinical remission. The precise pathogenesis of immunotherapy-associated BP is uncertain, and hypotheses include the presence of shared BP180 antigen on tumor cells in addition to B- and T-cell activation with secondary autoantibody production. Intense pruritus is often prominent and can either precede or accompany the blisters.

The time to onset of bullous eruptions varies widely, but typically arises in week 13-14 of treatment. Other blistering reactions include bullous lichenoid dermatitis, linear IgA bullous dermatoses (LABD), bullous erythema multiforme, and epidermolysis bullosa acquisita. These reactions are delayed and may take more than 6 months before becoming clinically apparent.

In most cases, immunotherapy associated BP requires protracted systemic treatment and interruption or complete discontinuation of immunotherapy to achieve successful remission. A goals of care discussion is crucial as switching to second-line chemotherapy risks progression of malignancy, and untreated BP may cause fatal complications. The risks and benefits need to be weighed and multidisciplinary management required.

The association between autoimmune toxicity and therapeutic response is unclear as there are a lack of prospective studies in the literature. Case reports cite positive tumor response or stable tumor burden in patients who develop cutaneous toxicities or flares of immune-mediated diseases (e.g. psoriasis, vitiligo, or sarcoidosis) while receiving PD-1/PDL-1 therapy. Some claim increased anti-tumoral response or stable disease despite discontinuation or interruption of immunotherapy.

Management of PD1/PDL1-inhibitor associated BP depends on severity and total body surface area affected. The use of topical corticosteroids is recommended for mild to moderate rash (grade 1 or 2). Widespread disease typically requires the addition of systemic steroids, discontinuation of immunotherapy, as well as initiation of rituximab. The

literature has not cited a reduced anti-tumoral response with low dose steroids of less than 0.7mg/kg/day, however, rituximab is a useful steroid-sparing option as it preferentially affects CD20+ cells, ultimately inhibiting antibody production. ¹

When considering pembrolizumab in patients with a history of autoimmune bullous disease, it is important to discuss potential reactivation of their lesions and closely monitor for flares. If reactivation occurs, rituximab can be considered in recalcitrant cases, especially if concomitant immunotherapy is required in the setting of a co-existent aggressive tumor and widespread BP. In patients where the tumor is likely to recur, it is important to weigh the risk of tumor progression and death against the risk of escalating to rituximab treatment, which increases risk of infection and development of progressive multifocal leukoencephalopathy (PML).

References

1. Apalla, Zoe, et al. "Management of immune checkpoint inhibitor-induced bullous pemphigoid." *Journal of the American Academy of Dermatology* 84.2 (2021): 540-543.
2. Lopez, Adriana T., et al. "A review of bullous pemphigoid associated with PD-1 and PD-L1 inhibitors." *International journal of dermatology* 57.6 (2018): 664-669.
3. Naidoo, Jarushka, et al. "Autoimmune bullous skin disorders with immune checkpoint inhibitors targeting PD-1 and PD-L1." *Cancer immunology research* 4.5 (2016): 383-389.
4. Siegel, Jacob, et al. "Bullous disorders associated with anti-PD-1 and anti-PD-L1 therapy: A retrospective analysis evaluating the clinical and histopathologic features, frequency, and impact on cancer therapy." *Journal of the American Academy of Dermatology* 79.6 (2018): 1081-1088.
5. Sowerby, Laura, et al. "Rituximab treatment of nivolumab-induced bullous pemphigoid." *JAMA dermatology* 153.6 (2017): 603-605.
6. Thomsen, Kenneth, et al. "Bullous pemphigoid as an adverse reaction to pembrolizumab: two case reports." *Case reports in dermatology* 10.2 (2018): 154-157.

Presented by Kumar Nadhan MD, Allison Wang MD ,and Warren Piette MD

History of Present Illness

A 47-year-old healthy woman presented with 4 months of burning sensation of the tongue. Her symptomatology also localized to the hard palate and lips and worsened with spicy or acidic foods. She had been prescribed clotrimazole, prednisone, diphenhydramine, and lidocaine jelly without improvement.

Past Medical History

No past medical history

Review of Systems

Negative for menstrual irregularity, melena, hematochezia, hematuria, dry eyes, vaginal dryness, frequent candidiasis

Physical Exam

Buccal Mucosa	Normal
Palate:	Normal
Lips:	Normal
Tongue:	Shiny appearance and diffuse loss of the filiform papillae throughout the anterior 2/3rds of the dorsal tongue

Laboratory Data

The following labs were remarkable/abnormal:

Ferritin	3.04 ng/mL	[11-305.8 ng/mL]
Iron	26 µg/dL	[5-35 µg/dL]
UIBC	>450 µg/dL	[155-300 µg/dL]

Diagnostic studies

EGD:	1. Two inlet patches seen in the proximal esophagus; otherwise normal esophagus 2. Normal GE Junction 3. Patchy erythematous and atrophic appearing mucosa seen in the antrum, body and fundus. Biopsies taken for pathology. CLO (Urease) test obtained 4. Normal duodenal bulb and second portion of duodenum. Biopsies taken from the bulb and second portion to r/o malabsorptive disorder.
Colonoscopy:	Normal terminal ileum. Normal whole colon.

Pelvic ultrasound:

Within normal limits.

Diagnosis

Atrophic Glossitis secondary to Iron Deficiency Anemia

Treatment and Course

The patient was treated with ferrous sulfate 325mg mg TID and referred to gastroenterology and gynecology for further evaluation. Patient symptoms improved with iron supplementation and IDA was corrected.

Discussion

Atrophic glossitis (AG) is characterized by mostly loss of filiform papillae and sometimes the loss of fungiform papillae. The loss of filiform papillae causes increase sensitivity to chemical and physical stimuli. The eventual loss of fungiform papillae leads to alteration in taste.

AG can be caused by deficiency in the following nutrient: Iron, B12, riboflavin, pyridoxine, folate acid etc. In addition to nutritional deficiency, AG can also be associated with H. Pylori infections, xerostomia, and diabetes. It is imperative to check CBC, iron panel, B12, folate, and homocysteine to recognize potential underlying anemia or nutritional deficiency.

The differential of burning sensation of the tongue and dysgeusia is vast. While burning mouth/tongue syndrome usually has a normal appearance of tongue, other etiologies have distinct clinical findings. Median rhomboid glossitis is characterized by fixed smooth atrophic plaque in the center of the tongue. Geometric tongue, also known as benign migratory glossitis, is characterized by transient red plaques with accentuation of the borders with white plaques.

In this case, iron deficiency due to irregular menstruation was the underlying cause of the atrophic glossitis. It may be difficult to uncover a thorough menstruation history by relying on broad questions, e.g. is your menstrual cycle normal; as the patient may not understand the definition of "normal". In order to elicit a thorough menstruation history, a precise series of questions can be used:

- How frequent are your cycles?
- How many days between the first day of your period and the first day of your next period?
- How long do your periods last?
- How often are you changing your pads or tampons?
- Are they soaked by the time they are changed i.e. bleeding through the pads?

References

1. Chiang, C., Chang, J. Y., Wang, Y., Wu, Y., Wu, Y., & Sun, A. (2020). Atrophic Glossitis: Etiology, Serum autoantibodies, anemia, Hematinic Deficiencies, hyperhomocysteinemia, and management. *Journal of the Formosan Medical Association*, 119(4), 774-780. doi:10.1016/j.jfma.2019.04.015.
2. Erriu M, Pili FM, Cadoni S, Garau V. Diagnosis of Lingual Atrophic Conditions: Associations with Local and Systemic Factors. A Descriptive Review. *Open Dent J*. 2016;10:619-635. Published 2016 Nov 16. doi:10.2174/1874210601610010619.

3. Hasley S: A comparison of computer-based and personal interviews for the gynecologic history update. *Obstet Gynecol* 1995; 85: 494
4. Seehusen DA, Johnson DR, Earwood JS, et al. Improving women's experience during speculum examinations at routine gynaecological visits: randomised clinical trial. *BMJ* 2006; 333: 171-3

Presented by Cossette Joy MD and Shilpa Mehta MD

History of Present Illness

A 49-year-old man presented with a two-month history of an asymptomatic rash on his face, chest, and hands in addition to new painful ulcerations on his elbows. He reported an associated dry cough and weight loss due to dysphagia and anorexia.

Past Medical History

Neurocysticercosis as an adolescent
Idiopathic chronic tachycardia

Review of Systems

Positive for night sweats, weight loss, dysphagia with solid food, anorexia, hoarseness
Negative for fevers, weakness, shortness of breath, Raynaud's phenomenon

Physical Exam

Muscle strength:	Normal
Scalp:	Diffuse non-scarring alopecia
Eyelids:	Periorbital edema with violaceous erythema
Chest:	Ill-defined poikilodermatous patch
Back:	Violaceous reticulated patch
Elbows:	Right elbow with a well-circumscribed 2.7 x 3.2 cm ulceration with surrounding erythema and right elbow with a smaller 1.5 x 1.2 cm ulceration
Hands:	Interphalangeal joints with violaceous plaques with few scattered well-circumscribed ulcerations overlying joints Palms with violaceous erythema and hyperkeratotic papules on distal fingertips Cuticles without cuticular dystrophy or capillary changes
Feet:	First metatarsal phalangeal joint with an eroded, violaceous plaque with retiform borders

Laboratory Data

The following labs were remarkable/abnormal:

AST	70 u/L	[0-40 u/L]
ALT	68 u/L	[5-35 u/L]
LDH	360 u/L	[85-210 u/L]
CK	124 u/L	[0-163 u/L]
Aldolase	9.6 u/L	[0-8.1 u/L]
Ferritin	1,060.07 ng/mL	[23.9-336.2 ng/mL]
Myositis Antibody panel	MDA5 >100	[<11]
Erythrocyte sedimentation rate	91mm/hr	[0-26 mm/hr]

Histopathology

Right palm, punch biopsy:

- Diffuse stromal mucin deposition with evidence of thrombotic angiopathy in the deep dermis near the subcutaneous junction associated with early ischemic fat necrosis

Diagnostic studies

EMG:

No electrophysiologic evidence of a myopathy

Chest x-ray:

No acute cardiopulmonary process identified

PFTs:

No obstructive or restrictive defect

High resolution chest CT:

Borderline enlarged main pulmonary artery. Mild dependent atelectasis. Minimal peripheral scarring within the left upper lobe laterally. No lung consolidation or pleural effusion

Repeat high resolution chest CT:

Subpleural reticulations with few patchy ground glass opacities likely related to interstitial lung disease. No honeycombing. Dilated main pulmonary artery, suggestive of pulmonary hypertension

Video swallow study:

Pharyngeal dysphagia with decreased hyolaryngeal elevation and reduced base of tongue retraction

Transthoracic echocardiogram:

Left ventricle systolic function is normal. The estimated ejection fraction is 55-65%. Wall motion is normal; there are no regional wall motion abnormalities. Right ventricle is normal in size with normal systolic function

Diagnosis

Anti-MDA-5 dermatomyositis

Treatment and Course

In conjunction with rheumatology, the patient was initially treated with prednisone 60 mg taper with initial improvement in his transaminitis and dysphagia. Mycophenolate mofetil (MMF) was initiated as a steroid sparing agent and titrated up to a maximum tolerated dose of 1000 mg BID. His skin lesions were treated with topical and intralesional corticosteroids. Due to his history of persistent idiopathic tachycardia, a vasodilatory agent was contraindicated.

Unfortunately, the patient's clinical status slowly declined with worsening dysarthria, dysphagia, pulmonary symptoms, and progressive cutaneous ulcerations of the hands and feet. Rituximab was added to his therapeutic regimen. He received 1000 mg/m² IV weekly for two doses and 500mg/m² IV every six months for a total of three infusions. His cutaneous ulcerations nearly resolved, but his pulmonary symptoms continued to worsen. Patient failed a trial of methotrexate (MTX) 25 mg weekly, and continues to be on MMF 1000mg BID, prednisone 10 mg daily, and trimethoprim/sulfamethoxazole (TMP/SMX) for Pneumocystis pneumonia prophylaxis.

Although anti-MDA5 antibodies do not confer a higher risk for malignancy, guidelines recommend age-appropriate and symptom-directed malignancy screening. Given our patient's age, there is no age-appropriate malignancy screening. In regard to symptom-directed malignancy screening, our patient had normal pulmonary function tests (PFTs) in addition to two high-resolution CT-scans which demonstrated interval worsening of interstitial lung disease throughout the course of his disease. An echocardiogram was also preformed to assess for possible pulmonary arterial hypertension but was found to be normal. Patient has a pending appointment with otorhinolaryngology for assessment of his dysphagia.

Discussion

Dermatomyositis (DM) is a heterogeneous group of autoimmune disorders that most commonly affect the skin and muscles, with variable systemic involvement. Although DM is often characterized by classic cutaneous manifestations such as Gottron papules and a heliotrope rash, skin findings are variable. Without the characteristic cutaneous findings or myopathy, diagnosis of DM can be difficult. This poses a particular diagnostic challenge in patients with clinically amyopathic dermatomyositis (CADM), which has been reported to occur in at least 20% of adults with DM.

The presence of myositis-specific autoantibodies (MSAs) among patients with DM has emerged as a useful diagnostic and prognostic tool for clinicians, especially in CADM. Specifically, a variety of MSAs are associated with unique clinical phenotypes. It has been suggested that MSAs alone may accurately divide patients into clinically relevant DM-subtypes. This allows clinicians to tailor subsequent work-up for systemic manifestations without the need for a muscle biopsy.

One such recently described MSA that is associated with a unique mucocutaneous and systemic CADM phenotype is an autoantibody against the melanoma differentiation-associated gene 5 (MDA5). MDA5 is an RNA-specific helicase that recognizes viral nucleic acids, suggesting that a viral infection may be a key trigger in the development of CADM. MDA5 is also known to induce production of type 1 interferon (T1-IFN), which has been hypothesized to be central in the pathogenesis of the cutaneous and pulmonary manifestations of anti-MDA5 DM.

One of the most striking features of anti-MDA5 DM is cutaneous ulceration, which is found in up to 82% of reported cases. Anti-MDA5 DM is associated with specific patterns of ulceration, including hyperkeratotic digital pulp lesions and ulcerations within Gottron papules, on lateral nailfolds, and over the elbows and knees. As seen in our patient, these painful ulcerations are often recalcitrant to therapy and are a source of significant morbidity. Importantly, the presence of cutaneous ulceration among anti-MDA5 DM patients is the strongest predictor of developing ILD, which can be a life-threatening complication.

Another unique cutaneous manifestation of anti-MDA5 DM are painful palmar papules known as inverse Gottron papules. Such papules are most commonly located on the palms and palmar creases of fingers, and although are most often inflammatory, may present as macules, patches, or atrophic lesions on a violaceous or livedoid background. Our patient presented with these classic inverse Gottron papules, and a biopsy of one lesion demonstrated stromal mucin deposition with evidence of thrombotic angiopathy in the deep dermis associated with early ischemic fat necrosis. Similar findings have been reported in the literature and include intraluminal thrombosis and endothelial cell injury and fibrin deposition in vessel walls with a variable inflammatory infiltrate.

Other mucocutaneous features associated with anti-MDA5 DM include panniculitis, diffuse non-scarring alopecia, painful oral ulcers, and mechanic hands with lateral digit hyperkeratosis and fissuring. Because the cutaneous presentation of anti-MDA5 often differs from classic DM, the diagnosis and subsequent treatment may be delayed.

Early intervention is critical in these patients given their risk for systemic disease, specifically rapidly progressive ILD (RP-ILD) that is often refractory to treatment. RP-ILD is defined as progression of ILD by subjective symptoms or objective measures in a short timeframe of less than three months. A recent meta-analysis found that the presence of anti-MDA5 antibodies (anti-MDA5ab) has a pooled sensitivity of 83% and specificity of 86% for the

development of DM-associated RP-ILD, and patients who test positive for anti-MDA5ab have 20-fold higher odds of having RP-ILD compared with those who test negative. Other risk factors for RP-ILD include elderly age, decreased PaO₂/F_iO₂ ratio and elevated levels of serum ferritin.

Laboratory evaluation in anti-MDA5 DM patients may be helpful in management and prognosis. Specifically, serum ferritin levels, which are often elevated in these patients (including our patient), correlate with disease activity. It has been suggested that baseline ferritin levels greater than 1600 ng/mL are the best indicator of mortality. Therefore, this subset of patients should receive more aggressive therapy.

Patients must be screened for pulmonary disease with pulmonary function testing, followed by high resolution CT of the chest if any abnormalities are noted. Repeat interval screening is recommended every 3 to 6 months for the first year after diagnosis. The reported 6-month mortality in patients with RP-ILD is estimated at 59%. Our patient did not meet the criteria for RP-ILD but continues to have progressive pulmonary disease and worsening pulmonary symptoms despite aggressive therapy.

Early aggressive treatment has been shown to improve patient outcomes. Treatment regimens must be individually catered, usually requiring a combination of immunomodulators and immunosuppressants. MMF is typically used as the initial steroid-sparing agent in patients with evidence of ILD as it has been shown to normalize PFTs and resolve dyspnea with comparatively lower prednisone doses. Other treatment modalities that have been reported in the literature for severe pulmonary involvement include rituximab, cyclophosphamide, calcineurin inhibitors, and intravenous immunoglobulin. For refractory cutaneous DM, intravenous immunoglobulin in combination with MMF has been used successfully in a small cohort of patients. Additionally, vasodilators such as nifedipine may be added to address the underlying vasculopathy. Data suggesting that overexpression of the T1-IFN pathway is critical in the pathogenesis of anti-MDA5 DM may offer new treatment strategies in the future.

In conclusion, anti-MDA5 DM presents with distinctive mucocutaneous and systemic features. These patients are at significant risk for ILD and RP-ILD, which may be fatal. It is, therefore, essential for dermatologists to recognize this unique variant of DM to be able to properly screen and manage these patients.

References

1. Chen L, Owens K, Murina A. Anti-MDA5 antibody-positive dermatomyositis presenting as unilateral eyelid edema. *JAAD Case Rep.* 2020;6(9):909-911. Published 2020 Jul 22.

2. Femia AN, Eastham AB, Lam C, Merola JF, Qureshi AA, Vleugels RA. Intravenous immunoglobulin for refractory cutaneous dermatomyositis: a retrospective analysis from an academic medical center. *J Am Acad Dermatol*. 2013;69(4):654–657.
3. Fiorentino D, Chung L, Zwerner J, Rosen A, Casciola-Rosen L. The mucocutaneous and systemic phenotype of dermatomyositis patients with antibodies to MDA5 (CADM-140): a retrospective study. *J Am Acad Dermatol*. 2011;65(1):25–34.
4. Hayashi M, Kikuchi T, Takada T. Mycophenolate mofetil for the patients with interstitial lung diseases in amyopathic dermatomyositis with anti-MDA-5 antibodies. *Clin Rheumatol*. 2017;36(1):239–240.
5. Huang K, Vinik O, Shojania K, et al. Clinical spectrum and therapeutics in Canadian patients with anti-melanoma differentiation-associated gene 5 (MDA5)-positive dermatomyositis: a case-based review.
6. Kurtzman DJB, Vleugels RA. Anti-melanoma differentiation-associated gene 5 (MDA5) dermatomyositis: A concise review with an emphasis on distinctive clinical features. *J Am Acad Dermatol*. 2018;78(4):776–785.
7. Li L, Wang Q, Wen X, et al. Assessment of anti-MDA5 antibody as a diagnostic biomarker in patients with dermatomyositis-associated interstitial lung disease or rapidly progressive interstitial lung disease. *Oncotarget*. 2017;8(44):76129–76140.
8. Mariampillai K, Granger B, Amelin D, et al. Development of a New Classification System for Idiopathic Inflammatory Myopathies Based on Clinical Manifestations and Myositis-Specific Autoantibodies. *JAMA Neurol*. 2018;75(12):1528–1537.
9. Moghadam-Kia S, Oddis CV, Aggarwal R. Anti-MDA5 Antibody Spectrum in Western World. *Curr Rheumatol Rep*. 2018;20(12):78
10. Ono N, Kai K, Maruyama A, et al. The relationship between type 1 IFN and vasculopathy in anti-MDA5 antibody-positive dermatomyositis patients. *Rheumatology (Oxford)*. 2019;58(5):786–791.
11. Sun WC, Sun YC, Lin H, Yan B, Shi GX. Dysregulation of the type I interferon system in adult-onset clinically amyopathic dermatomyositis has a potential contribution to the development of interstitial lung disease. *Br J Dermatol*. 2012;167(6):1236–1244.

Presented by Benjamin Falck MD and David Othman MD

History of Present Illness

A 37-year-old man with no past medical history presented with a 2-day history of lip and tongue swelling of sudden onset that progressively worsened. In addition, he noted significant pain and a right-hand rash. The patient tried diphenhydramine without any relief. He denied any fevers, chills, dysphagia, odynophagia, or new medications or foods.

Past Medical History

No known past medical history

Medications

None

Allergies

NKDA

Social History

Tobacco (pack/day): Denies
Drugs: Denies recreational use
Alcohol: Denies
Occupation: Works as a sales rep

Review of Systems

Negative for fever, chills, cough, dysphagia, odynophagia, dyspnea, chest pain, shortness of breath
Positive for occasional palpitations

Physical Exam

Lips and cheeks with significant edema and erythema. Lips with fibrinous debris, no hemorrhagic crusting
Tip of tongue with few clear vesicles
Conjunctiva clear
Neck with photodistributed bright red patches
Right second digit with circumferential tense bullae
Right third digit with round erythematous targetoid lesion with darker border

Laboratory Data

The following labs were remarkable/abnormal:
Urine toxicology Negative
HSV DNA Negative

Histopathology

RIGHT THIRD DIGIT, PUNCH BIOPSY:
Rare solitary intraepidermal apoptotic keratinocyte and scattered stromal mononuclear cells.

Comment: The current tissue slides do not reveal a bullous. An interface dermatitis is not seen. There is a paucity of inflammatory infiltrate that is mainly composed of scattered stromal mononuclear cells. However, the detection of a rare solitary intraepidermal apoptotic keratinocyte is in keeping with a photo-related dermatosis.

DIRECT IMMUNOFLUORESCENCE; NEGATIVE

Radiology

CT MAXILLOFACIAL WITH CONTRAST, HEAD:

Localized, marked angioedema of the lips. No localized fluid collection. Patent airway.

Diagnosis

Orofacial and digital frostbite due to inhalant abuse

Treatment and Course

The patient was admitted to the MICU for airway protection and treated with a steroid taper given low concern for infection. However, the patient decided to leave against medical advice and was given a prednisone taper, lidocaine swish/swallow, and diphenhydramine upon leaving.

Discussion

Inhalant abuse refers to the intentional inhalation of a volatile substance to produce intoxication. The term "inhalant" encompasses a number of chemically diverse substances including the broad category of solvents, liquids that become gas at room temperature and atmospheric pressure. Common solvents, such as fluorocarbons, have become popular propellants for many aerosolized household cleaning products. Given the ease with which these products can be found in the home and workplace, they are among the most commonly abused drugs by adolescents, second only to marijuana. Inhalants can be abused through a variety of methods including spraying the substance into the nose or mouth directly from the container ("sniffing"/"spraying"), via a bag ("bagging"), or with a solvent soaked rag placed over the mouth ("huffing"). Common aerosol propellants are low boiling point gases stored as liquids under pressure. When the canister trigger is depressed, the contents vaporize at atmospheric pressure, causing rapid evaporative cooling. Sniffing or spraying poses the unique risk of frostbite as the liquified gas can come into direct contact with skin and mucosa. The extent of cryoinjury is dependent on duration of exposure, temperature of the vapors, and distance from the cold source. More severe exposures are typified by intense angioedema and blistering, with concern for airway obstruction in the case of upper airway involvement. It is important to identify the household product being abused in order to identify the specific propellant and to anticipate its possible complications. The fluorocarbon implicated in this case, 1,1,1,2-tetrafluoroethane (HFC-134a), was initially investigated in the 1960s as an anesthetic and as such, we hypothesize that its anesthetic quality, together with its effect as a CNS depressant and anoxic insult, contributed to prolonged freezing cold exposure.

Identifying inhalant abuse can be difficult, especially if not disclosed by the patient, as physical signs may be subtle or absent in less severe cases. As with other external insults, a unique distribution pattern may be the only clue. The presence of perioral, perinasal, and/or digital frostbite, especially in an adolescent, should raise suspicion for volatile substance abuse. Additional signs to consider include nail discoloration, chemical odors, and a periorificial papular eruption known as "glue sniffer's rash".

References

1. Anderson C, Gloomis G. Recognition and Prevention of Inhalant Abuse. *Am Fam Physician*. 2003 Sep 1;68(5):869-874
2. Williams J, Storck M, et al. Inhalant abuse. *Pediatrics*. May 2007, 119 (5) 1009-1017; DOI: <https://doi.org/10.1542/peds.2007-0470>
3. Chan S, Alfonso K, Comer B. Upper aerodigestive tract frostbite from inhalation of automotive nitrous oxide. *Ear, Nose & Throat Journal*. September 2018

4. Koehler M, Camille A. Henninger C. Orofacial and Digital Frostbite Caused by Inhalant Abuse. *Cutis*. 2014;93:256-260
5. Plumb J, Thomas R G. Sudden severe perioral swelling in an adolescent boy. *Clinical Toxicology*. 2013, 51, 379–380
6. NIDA. 2020, April 16. Inhalants DrugFacts. Retrieved from <https://www.drugabuse.gov/publications/drugfacts/inhalants>